

Macroenvironmental influence on *Hepatozoon lacertilis* infectivity to lizard *Hemidactylus flaviviridis*

Author Details

N. Gupta (Corresponding author)	Department of Animal Science, M.J.P. Rohilkhand University, Bareilly - 243 006, India e-mail: guptagrawal@rediffmail.com
M. Bhaskar	Department of Animal Science, M.J.P. Rohilkhand University, Bareilly - 243 006, India
D.K. Gupta	Department of Zoology, Bareilly College, Bareilly - 243 005, India

Publication Data

Paper Received:
23 July 2009

Revised received:
25 May 2010

Accepted:
15 July 2010

Abstract

Hemidactylus flaviviridis Ruppell, 1835 (n= 199) sampled during different seasons from Bareilly, (Uttar Pradesh, India) were infected with a sporozoan parasite belonging to the genus *Hepatozoon* Miller, 1908. Four morpho-variants of the parasite, Type I, II, III and IV were identified on their growing pattern. When compared with earlier reported species, the parasite could be characterized taxonomically by its comparatively greater length 17.35 (13.57-21.30) μm and width 7.51 (5.59-10.11) μm , unusual larger size of parasite nuclear length 8.86 (4.75-15.83) μm and width 3.55 (2.14-5.11) μm and cytomorphological differences. These characteristics warrant creation of a new species and was named *Hepatozoon lacertilis* sp. nov. The morpho-variants, their effect on host cell and host nuclei are clearly illustrated. The influence of macroenvironmental factor (host sex) on parasitic infectivity indicated that it was 7.14% prevalent in male and 6.25% in female *Hemidactylus flaviviridis*.

Key words

Hemidactylus flaviviridis, Macroenvironment, *Hepatozoon lacertilis*

Introduction

The genus *Hepatozoon* Miller, 1908 (Apicomplexa : Adeleida) is a collection of blood parasites that has been described from every group of terrestrial vertebrate and from a wide range of haematophagous invertebrates (Levine, 1988). More species of haemogregarines have been described from lizards than any other group of vertebrates except snakes (Smith, 1996). Species of this genus of haemogregarine parasites have been described from all continents of the world (Bashtar *et al.*, 1983; Dollahon *et al.*, 1996; Smith, 1996; Telford *et al.*, 2001). Moco *et al.* (2002) evaluated the importance of morphology and morphometry of the gametocytes for the characterization of *Hepatozoon* species and analysed the morphologic changes induced in the erythrocytes by the parasites. Sloboda *et al.* (2007) described *H. ayorgbor* from *Python* and traced its life cycle in *Culex quinquefasciatus*. Telford (2010) recorded three new *Hepatozoon* species from Florida kingsnake. However, there are not many reports of *Hepatozoon* species from India

(Saratchandra, 1981; Gupta *et al.*, 2006). *Haemogregarina choudharyi* was recorded as a new species from the erythrocytes and lung tissues of *Lissemys punctata* (Spotted flapshell turtle) in Balina, West Bengal India by Ray and Bhattarcharjee (1984). The present study was conducted to observe the morphological peculiarities of an unstudied *Hepatozoon* species in *Hemidactylus flaviviridis* and to place the parasite in an appropriate taxometric platform.

Parasite prevalence and host ecology has been a neglected area of research. Studies on host-parasite interaction have mainly focused in the fields of population regulation (Anderson and May, 1979) and co-evolution (Toft and Kartar, 1990). The role of parasites in sexual selection was reviewed by Clayton (1991). Studies on haematozoan parasites of lizards are infrequent specially in relation to macro-environmental factors. Therefore, investigations were conducted on blood parasites of the wall lizard *Hemidactylus flaviviridis* and the sex of the host was selected as a macro-environmental factor to observe its influence on the parasite, *Hepatozoon*.

Materials and Methods

Hemidactylus is a genus of the family of geckos (Gekkonidae). The geckos are found in all the tropical regions of the world. Average length of the lizard is 10 inches and is characterized by a broad and flat head, vertical ear opening, moderately long tail and minute and smooth scales. The host was selected as an experimental research model due to its easy availability in the area and also research on blood parasite fauna of lizard has long been recognized, yet our knowledge on the distribution of haemoparasites in the lizards of the area are far from adequate.

Hemidactylus flaviviridis, (Family : Gekkonidae) (n=199; male 112, female 87) of different age groups juveniles (length 2-6 cm.) and adults (length 6-10 cm.) were collected from the urban areas of Bareilly (95), Mirzapur (55) and Chandausi (49) cities of U. P. of India and were maintained in the animal house of Department of Animal Science. The lizards were housed in specially designed cages having tight seams and well-fitted lids and maintained at temperatures above 25°C. Care was taken to maintain the animals under proper air exchange. They were fed on field mosquitoes to satiation and provided dish water. Fresh blood was collected from toe snips or tail puncture in heparinised tubes, mixed with one drop of saline, covered with a coverslip, and examined microscopically to observe live parasites. Infected RBC's showing slow gliding movement in fresh blood indicated the presence of parasites. However, their presence was confirmed by preparing blood smears stained with Giemsa-eosin-methylene blue (buffer pH 6.6) that were examined using light microscopy (Gupta, 1986). The parasites were drawn to scale by camera lucida and photographed using a LEICA DMLB photoautomat under 1000 x magnification. The ecological terminology adopted is as proposed by the American Society of Parasitologists (Margolis et al., 1982). Nuclear displacement ratio (NDR) was calculated according to Ray and Choudhary (1984). The prevalence was calculated by dividing the total number of infected lizards multiplied by 100 with total number of lizards examined. The mean intensity was calculated by total number of parasites divided by 1000 RBC's.

Results and Discussion

Parasite profile: Host - *Hemidactylus flaviviridis*, Locality - Bareilly, Uttar Pradesh, India (longitude 28.35°N latitude 79.42°E), Site of infection - Blood, Holotype - ZSI/ NRS/ IV.383, Paratype - SI/ NRS/ IV.384, (Zoological Survey of India, Northern Regional Station, Dehradun India), Etymology - The species *H. lacertilis* sp. nov. has been named after the sub order to which the host species belongs. Prevalence - 6.73%, Mean Intensity - 1.8 par/1000 RBC's

Morphology of Hepatozoon: Based on permanent blood smear examinations, following gamogonic stages of *Hepatozoon* were identified :

Type I - Young and slender forms: These were immature forms, slender and elongated in shape with rounded ends, nucleus situated towards one end of the body (Fig. 1a). Occasionally, forms slender

in the middle and broader at the ends visible, one aberrant form without nucleus was also observed. Notch present along one margin of the parasite membrane, in some, a protuberance was also visible. Nucleus elongated with rounded ends, densely packed chromatin granules, clear cytoplasm and no granulation. Central host nucleus and divided parasite nuclei were also visible. The nucleus attached towards the lateral side of parasite and host cell nucleus displaced towards one end of the RBC (Fig. 1b), however centrally placed host nucleus (Fig. 1c) or lateral to the parasite were also available. The host cell was spherical, bulging towards one end or in a stage of disintegration and were enucleated. Parasites were 15.185 (12.61-16.42) μm in length and 3.29 (2.38 – 4.28) μm in width. Parasite nucleus was 6.89 (6.42 – 8.09) μm in length and 2.45 (1.66 – 2.85) μm in width while NDR was 0.04. The prevalence of this form was 18%.

Type II - Growing forms: The growing forms were broader than young and slender forms with rounded ends, in some cases, one end pointed or tapering. The parasite was found situated in middle lateral, obliquely (Fig. 2a) or shifted towards one pole and did not lie along any axis of the host cell. A hanging parasite nucleus was visible (Fig. 2b) and seen to protrude out from one end of the body with densely packed chromatin granules. Host nuclear position varied being central or towards one end of the body (Fig. 2a). Parasite displaced the host nucleus obliquely (Fig. 3a), laterally (Fig. 3b) or towards the poles (Fig. 2a). The shape of host nucleus was oval (Fig. 3b), elongated, broad, bean-shaped, irregular in polar position and twisted obliquely. In rare specimens, host cell was enucleated. Abnormal forms with indented body on one side and knob like projections towards one end were also visible. Type II form was 15.44 (12.38 – 17.85) μm in length and 5.87 (4.28 – 7.14) μm in width and nuclear length 7.35 (5.71 – 8.57) μm and width was 2.89 (2.61 – 4.04) μm . Nuclear displacement ratio was 0.10 and their prevalence was 32%.

Type III - Mature forms: Type III forms were the most matured forms, broad in shape with rounded ends (Fig. 4a), occupying major part of RBC. Parasite was wavy and opposite ends showed concavity. They were long with round ends (Fig. 4b), twisted and in close proximity with host nucleus. Occasionally, parasite had beak or a knob like projection at one end or two small projecting bodies along the lateral margin (Fig. 5a). The parasite nucleus curvature corresponded to the curvature of the parasite and sometimes host nucleus also curved with the parasite. Parasite's nucleus was granular and deeply stained. Pattern of granulation was band like, median above the nucleus, lateral on one side or on both sides. Parasite's nuclear position was lateral or away from the cell boundary with beak like projection pointed towards one end or short and hanging or lying subterminally. Host nucleus was oval, oblong or bean-shaped with unusual shapes of heart, spindle, conical or laterally compressed host nuclei. Mature form displaced the host nucleus laterally (Fig. 4a), towards the long axis of the host cell in or polar positions. Host nucleus was apical (Fig. 4b), lateral (Fig. 4a) or host cell with dividing nucleus (Fig. 5b).

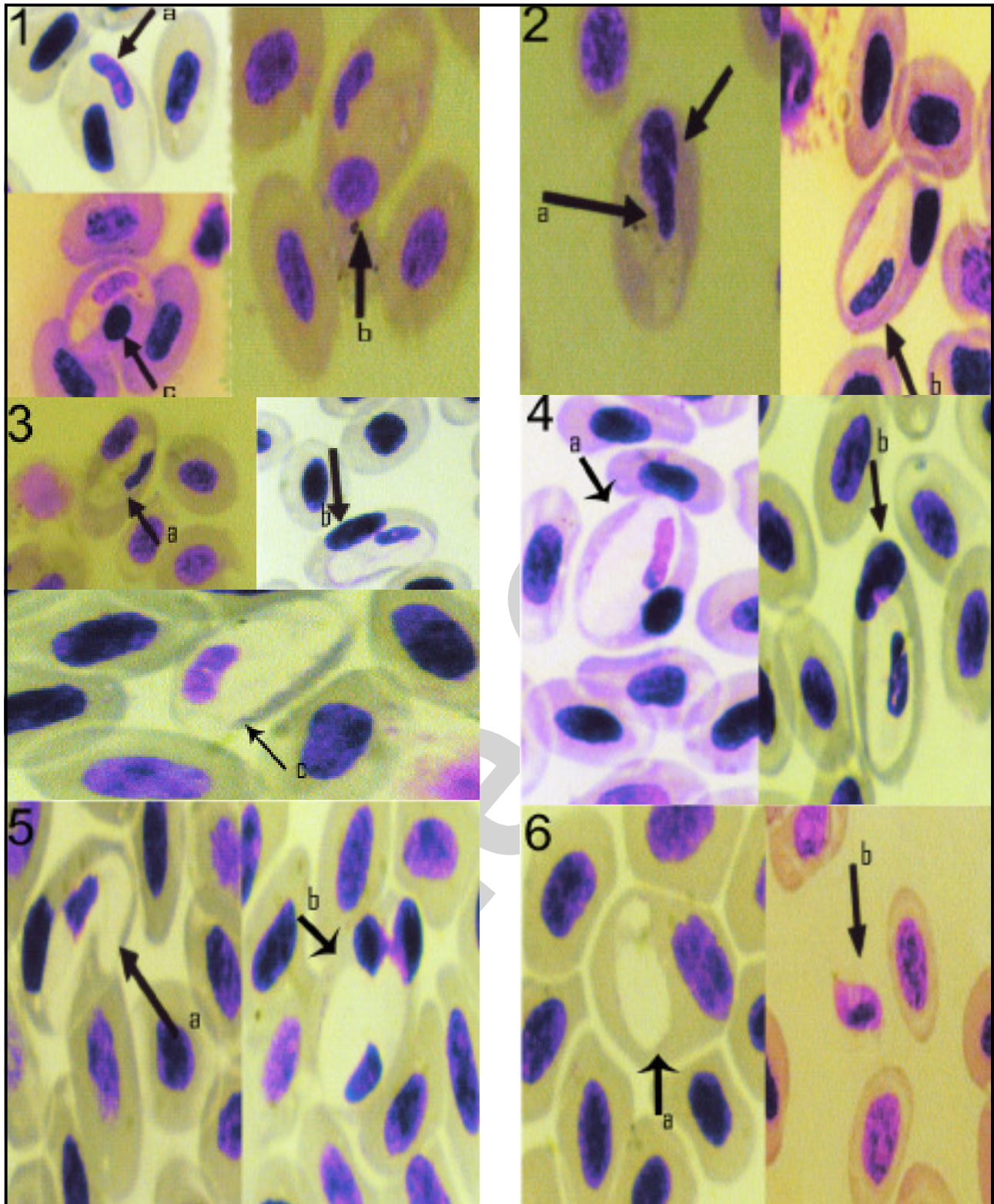


Plate: Photomicrographs of *Hepatozoon lacertilis* sp. nov. (X 1000). Fig. 1: Young and Slender forms: (a) Nucleus situated towards one end of the body; (b) Host nucleus situated apically; (c) Spherical host nucleus occupying central position; Fig. 2: Growing form: (a) Host and parasite nucleus shifted towards poles; (b) Hanging nucleus; Fig. 3: Growing form: (a) Showing nucleus situated obliquely; (b) Host nucleus displaced laterally; (c) Enucleated host cell. Fig. 4: Mature form: (a) Rounded ends of parasite body with laterally placed spherical host nucleus; (b) Host nucleus shifted apically; Fig. 5(a): Mature abnormal form: with subterminal knob like projection; (b) Host cell with dividing nucleus; Fig. 6(a): Enucleated mature form; (b): Extracellular elongate form

Host and parasite nuclei were parallel or adjacent to each other. Enucleated parasites were spotted rarely (Fig. 6a). RBC's shape varied, hypertrophied and occasionally showed irregular protuberances and spike like projections. Extra-ordinary large and mature forms were seen bulging from the red cell and an abnormal form with a sub-terminal knob like projection was also discernible. Mature forms were 18.17(14.76-23.09) μm in length and 8.33 (7.14 – 10.95) μm in width. Nuclear length was 9.59 (5.71– 19.28) μm and width 3.76 (2.38 – 4.52) μm while nuclear displacement ratio was 0.23. This form was 18% prevalent.

Type IV - Extra Cellular forms: Most parasitic stages were intracellular, a few forms emerged from the RBC and became extracellular. Escaping forms elongated apically (Fig. 6b), broader, narrower centrally with central nucleus. Nucleus granular, oval and deeply stained. Parasite escape position in RBC concave. Extracellular form condensed with twisted oblong nucleus. Nuclear chromatin granules deeply stained. Parasitic length 16.42 (14.28 – 18.57) μm and width 8.80 (8.09 – 9.52) μm . Nuclear length was 8.80 (7.61 – 10.00) μm and width 4.70 (4.28 – 5.23) μm . Only 2% of this form was prevalent.

A logical scheme for the classification of blood dwelling sporozoa in reptiles has historically been difficult to propose. Due to paucity of established life histories, very few essential diagnostic characters, including those in the arthropod definitive host, have been established. In actual life histories, the majority of reptilian haemogregarines have been named only on the basis of the parasite seen in the blood. Pessoa *et al.* (1971) described *Haemogregarina pallida* from the Brazilian snake, *Thamnodynastes pallidus* on the basis of parasitic stages in the erythrocytes. Consequently, most haemogregarines are described on the basis of gamogonic stages as observed in the blood.

Confusion regarding the applicability of the genus *Haemogregarina* and *Hepatozoon* has posed a problem for taxonomists. Smith (1996) transferred haemogregarines infecting vertebrates other than turtles and fish to the genus *Hepatozoon* and therefore the haemogregarines discovered from the blood of *H. flaviviridis* are placed in this genus as was also adopted for amphibian haemogregarines (Gupta *et al.*, 2006).

During the present investigations, *Hepatozoon* species observed from *H. flaviviridis* have been identified. The parasites were taxometrically compared with earlier reported species from reptilian hosts. In most hemogregarine descriptions, very few characters have been used to distinguish species, and often even measurements of the gamonts have not been stated (Telford *et al.*, 2001). The genus *Haemogregarina* has been described by different authors: *H. aegypti* from *Spalerosophis diadema* (Bashtar *et al.*, 1983), *H. ghaffari* from *Cerastus vipera* (Shazly *et al.*, 1994), *H. tarentannulari* from *Tarentola annularis* (Ramadan, 1995), *H. helmymohammedi* from *Tarentola annularis*, *Ptychodactylus hasselquisti* and *Hemidactylus flaviviridis* (Saoud *et al.*, 1995) and

Haemogregarina species from *Rhacodactylus leachianus* (Dollahon *et al.*, 1996).

From Florida several species have been identified : *H. punctatus* from *Diadophis punctatus*, *H. sauritus* from *Thamnophis sauritus sackenii*, *H. pictiventris* from *Nerodia fasciata pictiventris*, *H. seminatrici* from *Seminatrix pygaea*, *H. fasciatae* from *Nerodia fasciata pictiventris*, *H. sirtalis* from *T. s. sirtalis* (Telford *et al.*, 2001), *H. guttata* from *Elaphe guttata guttata* and *H. sistruri* from *Sistrurus miliaris barbouri* (Telford *et al.*, 2002).

A comparison of the present species with those mentioned above indicates that the present form can be differentiated from *H. waltirensis* (14.5 μm), *H. aegypti* (13-16 μm), *Haemogregarina* sp. (15.9 μm), *H. punctatus* [13.4 (12-16) μm], *H. pictiventris* [13.7 (11-16) μm] and *H. sistruri* [14.1 (12.6-15.8) μm] based on the greater length of the parasite under consideration [17.35 (13.57-21.30) μm]. Similarly, the parasite width of the present species [7.51 (5.59-10.11) μm] was larger than *H. palmeri* (1.5-2 μm) and *Haemogregarina* sp. (3.8 μm). Although the nuclear width is comparable to earlier species, but the most striking difference of the present form is its considerably larger nuclear length which reached up to 15.83 μm in some forms which has not been reported in any of the forms described earlier. The parasite is also unique in causing remarkable hypertrophy in the host cell. Lainson *et al.* (2003) observed no sexual dimorphism in *Hepatozoon caimani* observing only one form of the parasite in mature erythrocytes. The present finding as revealed by critical observation and taxo-metric description of four distinct types (Types I, II, III, IV) of the parasite contradicts the view that intraerythrocytic stages of *Hepatozoon* represent a single morphological entity. The morphological variants in the parasite structure including its nuclei, its effect on the host cell and host nucleus have been clearly described herein. It has been proposed that the morphologic characterization of the gamont in the peripheral blood of vertebrate host can be utilized as useful criteria for identification of *Hepatozoon* species in reptiles as reported by Moco *et al.* (2002) who based their studies on morphologic and morphometric analysis.

Based on the above speculation, the *Hepatozoon* parasite observed from the blood of *H. flaviviridis* cannot be identified as any of the above species and therefore, it is proposed that the species under consideration be given a new species status, *Hepatozoon lacertilis* sp. nov. with the specific characters as given in this account.

***Hepatozoon* infectivity in relation to sex of the host:** The prevalence of *Hepatozoon lacertilis* sp. nov. in male (7.14%) and female (6.25%) hosts *Hemidactylus flaviviridis* was investigated. Prevalence in different localities was 5.26% at Bareilly and 16.36% at Mirzapur. *Hemidactylus* of Chandausi were infection free. *Hepatozoon* infection was higher in the adult groups as compared to juvenile ones which may be due to their older age, greater contact with parasites during their life time also greater contact with the vector thereby increasing the chances of infection.

The difference in the prevalence of male and female host was insignificant ($p > 0.05$). It has been assumed that the measure of parasite prevalence reflects parasite resistance, that is, uninfected individuals should be resistant to parasites or are supposed to not having been exposed to parasites. Cox (1989) argued that interpreting blood parasite prevalence from single smears is extremely difficult. Forbes *et al.* (1994) studied the prevalence of blood parasites in male and female hosts in relation to different years and found that there was no significant annual variation in prevalence of either *Leucocytozoon*, *Trypanosoma* or microfilaria in adult males. Years and sex of hosts have been shown to relate to variation in prevalence of blood parasites in other extensive studies in lizards (Schall, 1990) and birds (Atkinson and Van Riper, 1991, Weatherhead and Bennett, 1991, 1992). Merila *et al.* (1995) analyzed the prevalence among different sexes and found no sexual differences in overall prevalence in the populations examined by them. Dawson and Bortolotti (2001) found that relationship between reproductive output and parasitism of American kestrels were also sex specific and opposite in nature. Males may spend more time in areas of high vector abundance, may have less time for performing anti-vector behaviors (Norris *et al.*, 1994). In this support, Amo *et al.* (2004) also suggested that the effect of parasites on their host population is essential for understanding their role in host population dynamics and ecology. During the mating season, the intensity of parasite infection was greater due to immunosuppressive effect of testosterone.

The overall result of the present investigation indicates that the difference in prevalence of *Hepatozoon* in male and female *Hemidactylus flaviviridis* was not significant, slightly higher infectivity occurring in males which are in agreement with Merila *et al.* (1995). A slightly higher infection in male lizards would indicate that they are more prone to parasitic infection as compared to females as observed by Dawson and Bortolotti (2001). It may be possible that the levels of parasitization with references to host sex may be due to chance phenomena or the parasitization may be related with the level of sex hormone as the female sex hormone may depress the level of parasitization, the mechanism of which is poorly understood.

The higher infectivity in males may be due to the immunosuppressive action of testosterone (Veiga *et al.*, 1998). Interestingly, the intensities were not much different between the sexes in young lizards as those weighing 0-5 gm were free from infection suggesting the role of hormones in adults. It is also possible that males may consume more vectors than females or have closer contact with infected invertebrate vectors thereby facilitating transmission. The higher intensities in males may also be responsible for maintaining the parasite presence within the host population (Ferrari *et al.*, 2004 and Salkeld and Schwarzkopf, 2005).

The present studies indicate that macro-environmental factor (sex of the host) may act as variables in determining *Hepatozoon* prevalence in *Hemidactylus flaviviridis*.

Although an insignificantly higher prevalence of parasites in male lizards has been demonstrated but sex developed difference in intensities have rarely been established. The preliminary investigation conducted herein merits further attention.

Acknowledgments

One of us (Manju Bhaskar) expresses her thanks to the Council of Scientific and Industrial Research, New Delhi for financial help rendered by awarding a SRF, fellowship.

References

- Amo, L., P. Lopez and J. Martin: Prevalence and intensity of haemogregarine blood parasites in a population of the Iberian rock lizard, *Lacerta monticola*. *Parasitol. Res.*, **94**, 290-293 (2004).
- Anderson, R.M. and R.M. May: Population biology of infectious diseases: Part I *Nature London* **280**, 361-367 (1979).
- Atkinson, C.T. and C. Van Riper: Pathogenecity and epizootiology of avian hematozoa : *Plasmodium*, *Leucocytozoon* and *Haemoproteus*. In: Bird-parasite interactions; Ecology, evolution and behaviour (Eds.: J.L. Loye and M. Zuk). Oxford University Press, New York. pp. 20-48 (1991).
- Bashtar, A.R., R. Boulus and H. Mehlhorn: *Hepatozoon aegypti* nov. sp. *Parasitol. Res.*, **70**, 29-41(1983).
- Clayton, D.H.: The influence of parasites on host sexual selection. *Parasitol. Today*, **7**, 329-334 (1991).
- Cox, F.E.G.: Parasites and sexual selection. *Nature London*, **34**, 289 (1989).
- Dawson, R.D. and G.R. Bortolotti: Sex specific associations between reproductive output and hematozoan parasites of American kestrels. *Oecologia*, **126**, 193-200 (2001).
- Dollahon, N.R., A.M. Bauer and A.P. Russell: Haemoparasitic protozoans (Plasmodiidae and Haemogregarinidae) from a new Caledonian gekkonid lizard, *Rhacodactylus leachianus*. *Can. J. Zool.*, **74**, 2104-2108 (1996).
- Forbes, M., P.J. Weatherhead and G.F. Bennett: Blood parasites of blue grouse: Variation in prevalence and patterns of interspecific association. *Oecologia*, **97**, 520-525 (1994).
- Ferrari, N., I.M. Cattadori, J. Nespereira, A. Rizzoli and P.J. Hudson: The role of host sex in parasite dynamics field experiments on the yellow necked mouse, *Apodemus flavicollis*. *Ecol. Lett.*, **7**, 88-94 (2004).
- Gupta, N.: *Trypanosoma colisi* sp.n. from a fresh water fish, *Colisa fasciata* Bloch. *Rev. Iber. Parasitol.*, **46**, 1-6 (1986).
- Gupta, N., R. Rastogi and S.I. Shalaby: Morphogenesis and erythrocytic development of a new *Hepatozoon* species from Indian frog, *Rana tigrina* of Northern India. *Egypt. J. Appld. Sci.*, **21**, 379-396 (2006).
- Lainson, R., I. Paperna and R.D. Naiff: Development of *Hepatozoon caimani* (Carini, 1909) Pessoa, De Biasi and De Souza, 1972 in the Caiman *C. crocodilus* the frog *Rana catesbeina* and the mosquito *Culex fatigans*. *Mem. Do Inst. Oswald.*, **98**, 1-11 (2003).
- Levine, N.D.: The protozoan phylum Apicomplexa. CRC Press Incorporation. Boca Raton, Florida. pp. 115-134 (1988).
- Margolis, L., G.W. Esch, J.C. Holmes, A.M. Kuris and G. Schad: The use of ecological terms in parasitology (Report of an ad hoc committee of the American Society of Parasitologists). *J. Parasitol.*, **68**, 131-133 (1982).
- Merila, J., M. Bjorklund and G.F. Bennett: Geographic and individual variation in haematozoan infections in the greenfinch, *Carduelis chloris*. *Can. J. Zool.*, **73**, 1798-1804 (1995).
- Moco, T.C., L.H. Dwyer, F.C. Vilela, T.H. Barrella and J.D. Silva: Morphology and morphometric analysis of *Hepatozoon* spp. (Apicomplexa : Hepatozoidae) of snakes. *Mem. Do Inst. Oswald.*, **97**, 1169-1176 (2002).

- Norris, K., M. Anwar and A.F. Read: Reproductive effort influences the prevalence of haematozoan parasites in great tits. *J. Anim. Ecol.*, **63**, 601-610 (1994).
- Pessoa, S.B., L. Saccheta and J. Cavalheiro: Note on haemogregarines from Brazilian snakes. On a new species of the genus *Haemogregarina* (S.S), parasite of *Thamnodynates pallidus* (Thunberg) and its development in mosquitoes. *Rev. Latinoam. Microbiol.*, **13**, 29-32 (1971).
- Ramadan, N.F., S.H. Mohammed and S.M. Fawzi: The ultrastructure of some stages of *Haemogregarina tarentannulari* infecting the gecko *Tarentola annularis*. *Qatar Univ. Sci. J.*, **15**, 379-387 (1995).
- Ray, R. and A. Bhattacharjee: *Haemogregarina choudharyi* sp. n. (Apicomplexa : Haemogregarinidae) in common pond water turtle, *Lissemys punctata punctata* (Bonnaterre) from West Bengal. *Acta Protozool.*, **23**, 67-74 (1984).
- Ray, R. and A. Choudhary: Haemogregarines of Indian Anurans. Technical Monograph No. 10, Zoological Survey of India, Kolkata. pp. 27-32 (1984).
- Salkeld, D.J. and L. Schwarzkopf: Epizootiology of blood parasites in an Australian lizard : A mark recapture study of a natural population. *Intl. J. Parasitol.*, **35**, 11-18 (2005).
- Saoud, M.F.A., N.F. Ramadan, S.H. Mohammed and S.M. Fawzi: Haemogregarines of Gecko in Egypt, together with a description of *Haemogregarina helmymohammedi* n. sp. *Qatar Univ. Sci. J.*, **15**, 131-146 (1995).
- Saratchandra, B.: Two new haemogregarines, *Haemogregarina waltairensis* n. sp. from *Calotes versicolor* (Darjin) and *H. ganapatii* n. sp. from *Lissemys punctata granosa* (Shoepff). *Proc. Ind. Acad. Sci.*, **90**, 365-371 (1981).
- Schall, J.J.: The ecology of lizard malaria. *Parasitol. Today*, **6**, 264-269 (1990).
- Shazly, A.M., A.K. Ahmed and H.M. Fayed: Life cycle of *Hepatozoon ghaffari* sp. nov. in *Viper cerastes vipera* and mosquito, *Culex pipiens*. *J. Union Arabian Biol.*, **1**, 215-239 (1994).
- Sloboda, M., M. Kamler, J. Bulantova, J. Votypka and D. Modry: A new species of *Hepatozoon* (Apicomplexa : Adeleorina) from *Python regius* (Serpentes: Pythonidae) and its experimental transmission by a mosquito vector. *J. Parasitol.*, **93**, 1189-1198 (2007).
- Smith, T.G.: The genus *Hepatozoon* (Apicomplexa : Adeleina). *J. Parasitol.*, **82**, 565-585 (1996).
- Telford, (Jr.) S. R.: Three new *Hepatozoon* species (Apicomplexa : Hepatozoidae) infecting the Florida kingsnake, *Lampropeltis gerula floridana*. *J. Parasitol.*, **96**, 162-169 (2010).
- Telford, (Jr.) S.R., J.F. Butler and R.S. Telford: *Hepatozoon* species (Apicomplexa : Hepatozoonidae) of the corn snake, *Elaphe guttata* (Serpentes : Colubridae) and the pigmy rattle snake, *Sistrurus miliaris barbouri* (Serpentes : Viperidae) in South Florida. *J. Parasitol.*, **88**, 778-782 (2002).
- Telford, S.R., E.J. Wozniak and J.F. Butler: Haemogregarine specificity in two communities of Florida snakes, with description of six new species of *Hepatozoon* (Apicomplexa : Hepatozoidae) and a possible species of *Haemogregarina* (Apicomplexa : Haemogregarinidae). *J. Parasitol.*, **87**, 890-905 (2001).
- Toft, C.A. and A.J. Kartar: Parasite host coevolution. *Trends Ecol. Evol.*, **5**, 326-329 (1990).
- Veiga, J.P., A. Salvador, S. Merino and M. Puerta: Reproductive effort affects immune response and parasitic infection in a lizard. A phenotypic manipulation using testosterone. *Oikos*, **82**, 313-318 (1998).
- Weatherhead, P.J. and G.F. Bennett: Ecology of parasitism of brown headed cowbirds by haematozoa. *Can. J. Zool.*, **70**, 1-7 (1992).
- Weatherhead, P.J. and G.F. Bennett: Ecology of red winged blackbird parasitism by haematozoa. *Can. J. Zool.*, **69**, 2352-2359 (1991).